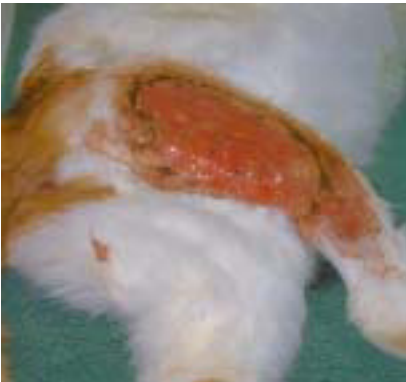

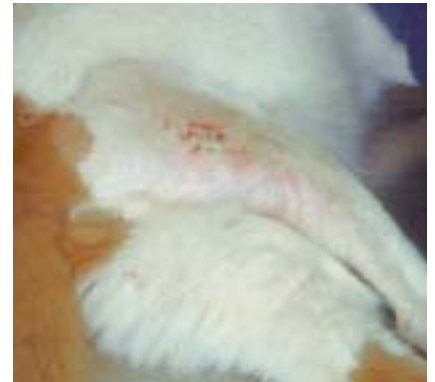Dermal



Left: 10 month old cat with excised abscess.

Right: 3 months after surgery.

Reference: Janine Badylak, USA.



Avian



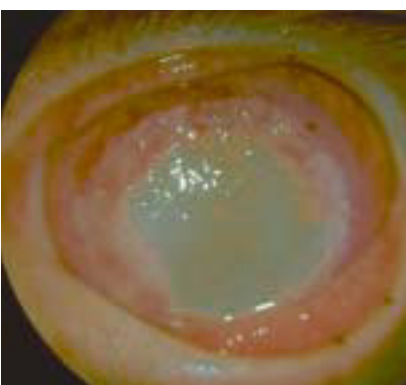Left: Barn owl with full thickness skin necrosis.

Right: After surgery.

*Reference: Stephen J. Divers
BSc(Hons) BVetMed CBiol MIBiol DZooMED
(Reptilian) MRCVS Diploma in Zoological
Medicine. Ithaca New York USA*



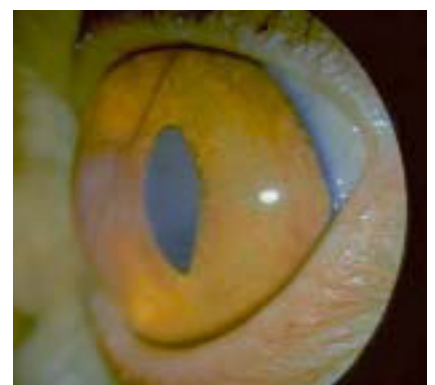
Ocular



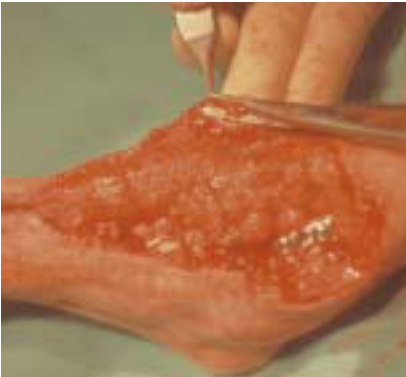Left: 3 year old persian cat presenting with deep stroma ulcer.

Right: 3 months after surgery.

Reference: Dr Monika Hund, Germany.



Dermal



Left: 10 month old crossbreed American Sheepdog with a degloving injury.

Right: 32 days after surgery.

Reference: Drs Michel Baron and Isabelle Valin, Clinique vétérinaire chirurgicale, Maisons Alfort, France.

